



## PATIENT

Chewy Smith

## SPECIES

Feline

## BREED

DLH

## SEX

FS

## AGE

12 y

## WEIGHT

7.26 lb

## INTERPRETED BY

Keith Blass, DVM, MS,  
DACVIM (Cardiology)

## IMAGING PERFORMED BY

Ashley Whitesell

## HOSPITAL NAME

Dickson AC

## REFERRING VET

Dr. Levine

## INVOICE

## DATE

6/2/26

## PRESENTING CLINICAL SIGNS

Grade 2/6 murmur.

## ECHOCARDIOGRAPHIC FINDINGS

2D, M-mode, and Doppler study.

Left atrial size is normal. The mitral valve is normal. Left ventricular wall thickness is normal. Left ventricular internal dimensions are normal. Left ventricular systolic function is normal. The aorta and aortic valve are normal. Right atrial and right ventricular dimensions are normal. The tricuspid valve appears normal, though trace tricuspid regurgitation is present. The pulmonary artery and pulmonic valve appear normal, though trace pulmonic insufficiency is present. No shunting lesions are visualized. No heartworms are visualized. No pericardial effusion or cardiac masses are seen.

ECG during echo: Sinus rhythm

LA - 14.3 mm  
IVSd - 2.8 mm  
LVPWd - 2.8 mm  
LVIDd - 12.7 mm  
LVIDs - 6.9 mm  
FS - 45.7%  
RA - 10.3 mm  
LVOT - 0.53 m/s  
RVOT - 0.69 m/s

## ASSESSMENT/RECOMMENDATIONS

Normal echocardiogram

This examination demonstrates no evidence of structural heart disease. While a definitive reason for Chewy's murmur was not identified, it's likely that her murmur is functional/innocent in nature, as no flow abnormalities that could result in the development of a pathologic murmur were appreciated in the image set.

No therapy is recommended based on this exam.

A recheck echocardiogram is recommended if the characteristics of Chewy's murmur change, or if other new physical exam and/or clinical abnormalities suggestive of the presence of cardiac dysfunction develop.



### PATIENT

Chewy Smith

### SPECIES

Feline

### BREED

DLH

### SEX

FS

### AGE

12 y

### WEIGHT

7.26 lb

### INTERPRETED BY

Keith Blass, DVM, MS,  
DACVIM (Cardiology)

### IMAGING PERFORMED BY

Ashley Whitesell

### HOSPITAL NAME

Dickson AC

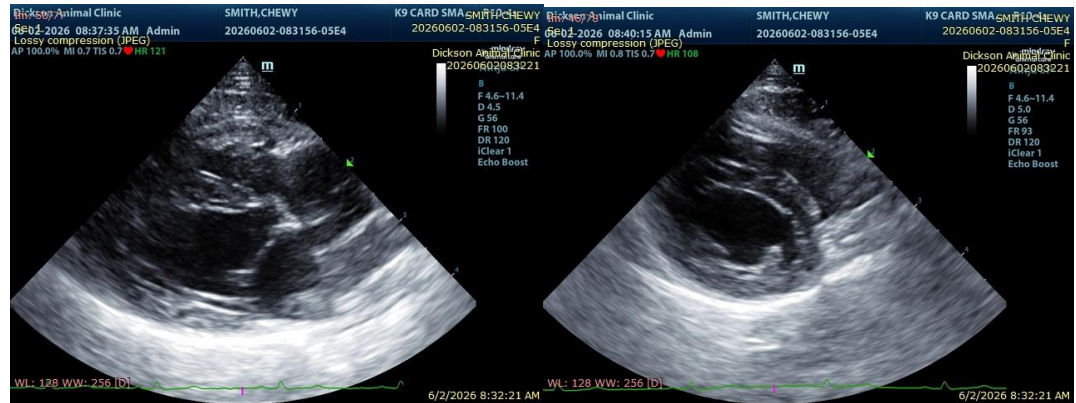
### REFERRING VET

Dr. Levine

### INVOICE

### DATE

6/2/26



The information and recommendations provided are based on the images presented by the referring veterinarian/sonographer. No evaluation can be communicated regarding pathology that was not visible in the image/video clips provided.

Thank you for this referral. If the clinical or image interpretation does not parallel your findings or if I can be of any further assistance please contact me.

Keith Blass, DVM, MS, DACVIM (Cardiology) [info@SonoPath.com](mailto:info@SonoPath.com)